

## Tuberculosis of Thyroid with Vocal Cord Paralysis: A Report of A Case

### *Vokal Kord Paralizi İle Seyreden Troid Tüberkülozu*

Gulden BILGIN<sup>1</sup>, Adnan HASANOGLU<sup>2</sup>, Bekir ÇAKIR<sup>3</sup>, Haluk TUMER<sup>2</sup>,  
Huseyin USTUN<sup>4</sup>, Ahmet KUSDEMİR<sup>2</sup>

*Department of Chest Diseases<sup>1</sup>, Department of General Surgery<sup>2</sup>, Department of Internal Medicine<sup>3</sup>  
Department of Pathology<sup>4</sup>, Ankara Training and Research Hospital, Ankara, Turkey*

**ABSTRACT:** Tuberculosis of the thyroid gland, a rare condition, was present in the case of a 45 year-old woman presenting her complaints as hoarseness and fever. We performed an operation and administered an antituberculosis treatment afterwards, observing a case of tuberculous abscess of the thyroid gland as a primary sited location copying thyroid malignancy with left vocal cord paralysis.

**Key Words:** Tuberculosis, Thyroid Gland, Vocal Cord Paralysis

**ÖZET:** Tiroid bezinde tüberküloz nadir bulunur. Ses kısıklığı ve ateş yakınması olan 45 yaşındaki kadın hasta opere edildikten sonra, antitüberküloz tedavi verildi. Olgumuzun, sol vokal kord paralizi olup, tiroid kanserini taklit eden, tiroid bezinde pimer yerleşimli tüberküloz absesi olduğu saptandı.

**Anahtar Kelimeler:** Tüberküloz, troid bezi, vokal kord paralizi

### INTRODUCTION:

Tuberculosis affecting the thyroid gland is a rare condition (1,2), occurring at a ratio of 0.1-0.4 per cent (established from a histological study of thyroid specimens resected) (3,4,5). Diagnosis is based on histological study and exhibition of the tubercle bacilli through biopsy or aspiration specimens. The most frequent and regular indication is that of swelling of the neck (6). Among pathological forms are cold abscess, multiple thyroidal granulomata, chronic fibrosing thyroiditis, goitre along with caseation and acute abscess with the least rarity (7).

Our study involves a case of thyroid tuberculosis with complaints about hoarseness and fever voiced by the patient.

### CASE REPORT

A woman of 45 made complaints of hoarseness and fever which she said had been going on for six months and of a three-month swelling on the anterior-left side of her neck. No indication of cough, chest pain, dyspnea and sputum production or dysphagia was detected, and neither was any

other medical history being elicited, including that of pyrexia, weight loss, and recent tuberculosis on the part of both the patient and her family.

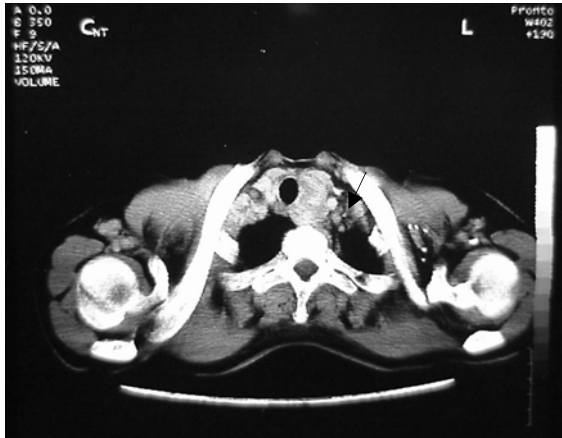During the initial physical examination, a palpable mass on the left thyroid lobe was detected with a temperature of 37, 5 C and PPD of the patient was 35 mm. An indirect laryngoscopic examination revealed a left vocal cord paralysis. While the thyroid gland was observed to be normal in size, an ultrasonography revealed a 21x20x31 mm cystic formation on the left lobe of the thyroid. On the other hand, a neck CT revealed a 35x32x28 mm hypodens mass located at the paratracheal and paraesophageal region of the left thyroid lobe (Figure 1). Moreover, fine-needle aspiration cytology (FNAC) demonstrated degenerated thyroid cells, and polymorphonuclear leukocytes with macrophages. These findings suggested an acute thyroiditis or abscess.

Initial laboratory results revealed slight leukocytosis (WBC count 10.10<sup>3</sup>, with 62.7% neutrophils, 30.1% lymphocytes, 5.7% monocytes, 0.7% eosinophils and 0.8% basophils). Thyroid function tests and other laboratory findings were normal.

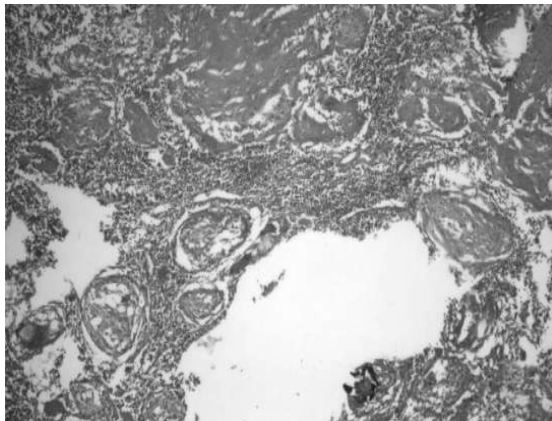
Patient was hospitalized for thyroid lobectomy as malignancy was suspected. A collar-neck incision was applied under general anesthesia, and the left thyroid lobe was detected to be bigger than the right one with the identification of the thyroid gland. The left lobe of the thyroid gland was adherent to the

thyroid and cricoid cartilages. Milky white pus leaked from the cyst to cavity as a result of the mobilization. We found that the cyst ranged from the left thyroid gland to the larynx in front of the cricothyroid joint. Therefore, we removed the left lobe of the thyroid gland totally.

Microscopically the excised thyroid specimen showed caseating epitheloid cell granuloma (Figure 2). PCR, an evaluation of the tissue, was applied to the fresh tissues and found to be positive for mycobacterium tuberculosis. Antituberculosis therapy was administered as Rifampin 600 mg, Isoniazid 300 mg, Pyrazinamid 3000 mg and Ethambutol 1250 mg. After antituberculosis chemotherapy was applied to the patient for ten months, she recovered from hoarseness. Hoarseness and fever disappeared on the first month of the postoperative examination.



**Figure 1.** A hypodens mass located on left lobe of thyroid is seen on neck CT



**Figure 2.** Histopathological appearance of caseating epitheloid cell granuloma (Hematoxylin & Eosin. X200).

## DISCUSSION

Tuberculosis of the thyroid gland is rare (1,2). Most of the cases appear secondary to systemic tuberculosis (8). Tuberculosis of the endocrine system is related to disseminated infection. Our case was peculiar only to thyroid. The definite reason why thyroid tuberculosis occur rarely is not obvious. The exact reason for the rarity of thyroid tuberculosis is unknown. Hypotheses in the literature include: (I) thyroidal colloid material possessing bactericidal action, (II) extremely high thyroidal blood flow and excess of iodine, (III) enhanced destruction of tubercle bacilli by increased physiological activity of phagocytes in hyperthyroidism, and (IV) oxygenation of the thyroid tissue (3). Most of the reported cases are diagnosed either post-operatively or during biopsy. We diagnosed the patient of ours after the operation. Although a broad range of manifestations may accompany thyroid tuberculosis, it is also likely to be asymptomatic. The most typical symptoms of the case are weight loss, night sweating, fever and fatigue (9). In our case, there was no symptom other than fever. No damage in thyroid function is common regardless of its being affected. In our case the thyroid function was not impaired.

Seven per cent of the cases of miliary tuberculosis involve the thyroid gland (6). Clinical and imaging features of tuberculosis in this region frequently interfere with carcinoma (4,6). It is presented mostly in focal caseous form and it imitates thyroid cancers and acute abscess (4). In the literature, some cases were reported who had thyroid cancers and thyroid tuberculosis contemporaneously (10). Diagnosis should be made by identifying the lesion histopathological and bacteriological methods. FNAC is a rapid and minimal invasive approach to diagnose extrapulmonary tuberculosis and has been used successfully in identifying tuberculous lesions in lymph nodes, thyroid, kidney, pancreas, vertebra and testis (6,11). CT and US revealed a cystic mass in left lob of thyroid in our patient, and FNAC revealed acute thyroiditis and abscess. The histopathological diagnosis was tuberculous abscess of thyroid gland and also PCR for Mycobacterium Tuberculosis was positive in the material. The mature tuberculous abscess of thyroid gland is suggested to be as a result of lymphohematogenic spread during primer infection.

Treatment of thyroid tuberculosis does not differ from that for various forms of the disease. The concomitant use of four effective drugs (rifampin, isoniazid, pyrazinamide, ethambutol) must be given

for two months, then must be prolonged (rifampin, isoniazid) with appropriate follow-up.

In conclusion, isolated tuberculosis involving the thyroid gland alone is rare. The compression effect of a mass may cause hoarseness, especially in the abscess form of thyroid tuberculosis. In the patients who have nodular or cystic lesion, demonstrated by CT or US, tuberculosis should be considered in differential diagnosis. If the patient is considered to have tuberculosis, bacteriological evaluation for mycobacterium should be performed and the patient should be examined for miliary tuberculosis. Combined therapy involving antituberculous agents and surgery must also be considered.

### REFERENCES

1. Emery P. Tuberculous abscess of the thyroid with recurrent laryngeal nerve palsy: case report and review of the literature. *J Laryngol Otol*, 1980; 94: 553-558.
2. Tas A, Yagiz R, Karasalihoglu AR. Thyroid gland tuberculosis with endolaryngeal extension: a case with laryngotracheal dyspnoea. *J Laryngol Otol*, 2005 Jan; 119 (1): 54-56.
3. El Malki HO, El Absi M, Mohsine R, et al. La tuberculose de la thyroïde. *Diagnostic et traitement. Ann Chir*, 2002; 127: 385-387.
4. Al-Mulhim AA, Zakaria HM, Hadi MSAA, et al. Thyroid tuberculosis mimicking carcinoma: report of two cases. *Surg Today*, 2002; 32: 1064-1067.
5. Mondal A, Patra DK. Efficacy of fine needle aspiration cytology in the diagnosis of tuberculosis of the thyroid gland: a study of 18 cases. *J Laryngol Otol*, 1995; 109: 36-38.
6. Magboo MLC, Clark OH. Primary tuberculous thyroid abscess mimicking carcinoma diagnosed by fine needle aspiration biopsy. *West J Med* 1990; 153: 657-659.
7. Johnson AG, Philipps ME, Thomas RJS. Acute tuberculous abscess of the thyroid gland. *Br J Surg*, 1973; 60: 668-669.
8. Iseman MD. Extrapulmonary tuberculosis. A clinician's guide to tuberculosis Philadelphia: Lippincott Williams & Wilkins, 2000. p. 145.
9. Khan EM, Haque I, Pandey R, Mishra SK, Sharma AK. Tuberculosis of the thyroid gland: a clinicopathological profile of four cases and review of the literature. *Aust N Z J Surg*, 1993; 63: 807-810.
10. El Kohen A, Essakali L, Amarti A, et al. Thyroid tuberculosis associated with papillary microcarcinoma of the thyroid gland: A case report. *Rev Laryngol Otol Rhinol (Bord)*, 2001; 122:205-208.
11. Thompson KS, Donzelli J, Jensen J, et al. Breast and cutaneous mycobacteriosis: diagnosis by fine-needle aspiration biopsy. *Diagn Cytopathol*, 1997; 17: 45 - 49.

