

Alkaptonuria: Effects of Physical Therapy in The Treatment of Low Back Pain

Alkaptonüriye Bağlı Bel Ağrısı Tedavisinde Fizik Tedavinin Etkinliği

İlknur YİĞİT¹, Deniz EVCİK¹, Vural KAVUNCU¹, Ender EVCİK²

¹ Kocatepe University, Faculty of Medicine, Department of Physical Medicine and Rehabilitation, Afyonkarahisar

² Afyon State Hospital, Department of Radiology, Afyonkarahisar.

ABSTRACT: Alkaptonuria is a rare hereditary disorder which may result with arthropathy in multiple joints. Clinical findings are similar to degenerative joint diseases. It mostly involves the spine and extremities especially large joints. There is no consensus in the treatment of the disease. In this case we present the effect of physical therapy program in the treatment of back pain and a four year follow up results.

Key Words: alkaptonuria, back pain, physical therapy

ÖZET: Alkaptonüre bir çok eklemde artropatiye yol açabilen, nadir görülen herediter bir hastalıktır. Klinik bulgular dejeneratif hastalıklarla benzerlik göstermektedir. Çoğunlukla omurga ve ekstremitelerde büyük eklemleri tutar. Hastalığın tedavisinde kesinleşmiş bir görüş birliği mevcut değildir. Bu olguda, bel ağrısı tedavisinde fizik tedavinin etkinliğini ve dört yıllık takip sonuçlarını bildirmektediriz.

Anahtar Kelimeler: Alkaptonüri, bel ağrısı, fizik tedavi

INTRODUCTION

Alkaptonuria is a rare autosomal recessive metabolic disorder of tyrosine with an estimated incidence of 1:250 000 to 1:1 000.000 (1). The pathology is characterized by the deficiency of the enzyme of homogentisic acid oxidase which results an increased accumulation of homogentisic acid (HGA) in blood (2). Its oxidation to benzoquinone acetic acid can bind collagen and can deposit in connective tissues. This cause a blue-black pigmentation which can affect various body parts such as sclera, heart valves, periarticular soft tissues, articular cartilage and called as "ochronosis" (3). Musculoskeletal manifestations are similar to degenerative joint diseases and usually involve the spine and large peripheral joints. Initial symptoms are mostly back stiffness and low back pain related to the involvement of intervertebral discs (4). Although there is no standard treatment method, low protein diet and ascorbic acid therapy are found to be effective in clinical trials (5). Sometimes major

symptoms are related to musculoskeletal pathology and patients undergo surgical treatment for severe arthropathy. Non surgical treatment modalities such as exercise and physical therapy are usually preferred in degenerative arthropathy. In this case we present the result of physical therapy on a patient with alkaptonuric back pain and four year follow up period.

CASE REPORT

A 50-year-old woman presented with low back and knee pain. She had hypertension since 6 years and chronic renal failure (because of childhood glomerulonephritis) since 10 years. Her family history included that her father had died due to chronic renal failure. She first attended our outpatient clinic 4 years ago with low back and knee pain. She had complaints of morning stiffness and pain on low back region. She had also bilateral knee pain while walking and standing upstairs. She gave no history of antimalarial or containing phenolic drug intake as these drugs may cause exogenous ochronosis. She was 154 cm and her body weight was 68 kg. On physical examination, sclera revealed a blue-black pigmentation. Urine examination confirmed the diagnosis of ochronosis as a dark coloration was observed when it was exposed to sunshine. On musculoskeletal examination she had

increased lumbar lordosis, and had paraspinal muscle spasm. Lumbar range of motion was painful and flexion was ½ limited. Extension, rotations and lateral flexions were limited at end points only. Straight leg raising test was negative for both sides. On knee examination movements of both knees were painful but there was no restriction in range of motion. Knee pain was assessed by 0-4 scale (0 means no pain, 4 means severe pain). Neurological examination was in normal limits. She was assessed as nonspecific low back pain and osteoarthritis. Then she was subjected to lumbosacral radiography in anteroposterior (AP) and lateral positions (Figure 1). There were disc space narrowing, generalized osteopenia, facet arthrosis and demonstrative intradiscal calcification at all levels in the lumbar spine. Also a weight-bearing AP radiography of the knees was performed (Figure 2). Changes in knees were similar to degenerative disease and no calcification was observed. Routine biochemical analysis such as whole blood count, erythrocyte sedimentation rate (ESR), C-reactive protein (CRP), liver and renal function tests were evaluated. Only renal function tests were abnormal in confirming the chronic renal failure. In order to reduce low back and knee pain a physical therapy program including transcutaneous electrical nerve stimulation (TENS)(20 min), hot pack (15 min), ultrasound (totally 10 min) were applied to the patient a total of 15 session (five times a week for 3 weeks). Also low back (pelvic tilt and flexion exercises) and quadriceps strengthening exercise program (isometric and isotonic) were applied to her. She had physical therapy two times during this four year period.

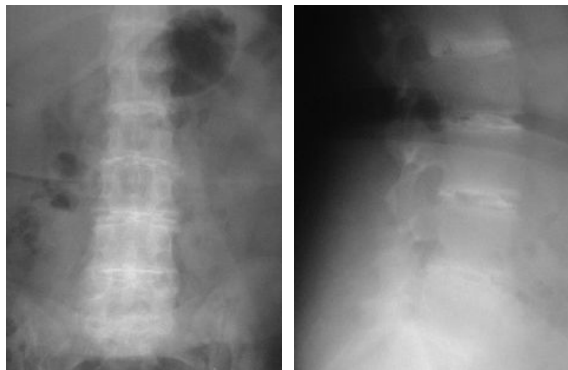


Figure 1. Radiographics of the lumbar spine (A) anteroposterior (B) lateral view

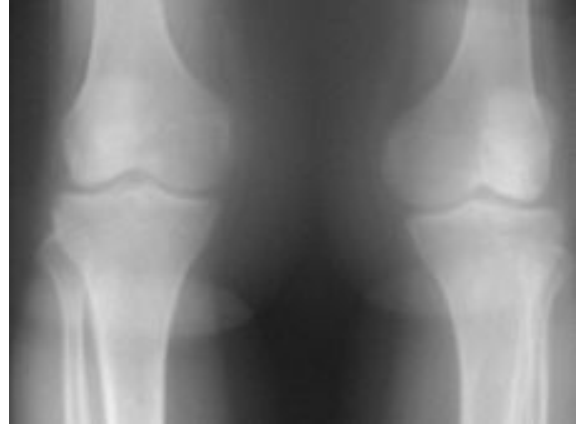

Figure 2. Radiologic view of the knees in anteroposterior position

DISCUSSION

It is well known that in ochronosis there is a deficiency in HGA oxidase which causes an elevation in the plasma levels of HGA. As a result, kidneys excrete the HGA into the urine and the diagnostic oxidized blue-black pigment causes dark coloration. The deposition of ochronotic pigmentation increases the vulnerability of the cartilage and leads to fragmentation of both articular surface and intervertebral disc. The clinical findings usually appear after the fourth decade (6, 7). The major radiologic features are osteoporosis, abnormal calcification and arthropathy. Abnormal calcification and peripheral bony bridges in the annulus fibrosis are most prominent in lumbar intervertebral discs. Large peripheral joints including knees, shoulders and hips are usually involved with changes resembling osteoarthritis. Ochronosis may cause a rapidly progressing destructive peripheral arthropathy. Also arthropathy of knee may be differentiated from degenerative diseases by involvement of lateral or symmetric of both lateral and medial tibiofemoral compartments (7, 8). In our case during 4 years she had complaints about knee pain and stiffness but there is no obvious cartilage calcification on X-ray. Sometimes the clinical findings may be seen independent from radiologic progression (1). Initial symptoms mostly involve the spine and the involvement of the large joints may follow up about 10 years after the spinal changes (9). In a few cases lumbar disc herniation have been reported as a first and major pathology in which there were no other sign and symptoms of alkaptonuria (10).

In alkaptonuria the treatment protocol is unclear. Restriction of the protein intake daily decreases the urinary HGA levels. It is reported that an improvement occurs in both clinical symptoms and radiologic changes by a low protein diet (5,11). However diet alone is not enough to reduce the back pain. In chronic diseases, the quality of life is very important. Chronic pain and limited joint mobility are major factors that affect disability. In literature, there is one case with ochronosis who had physical therapy program. The patient had spinal manipulation and massage on low back region and interferential current and phonophoresis on knee and ankles. Patient was periodically treated for two years and had a decrease in pain and muscle spasm (9). In our case we observed that a physical therapy program (TENS, hot pack, ultrasound and exercise) is very effective in symptom management. It is especially effective in pain relief as after physical therapy program, patient reported a decrease in back pain (1;minimal pain) and knee pain(0;no pain). Also in our case there was a major problem in using nonsteroidal anti-inflammatory drugs because of her chronic renal failure. So in pain relief we did not have multiple options and decided applying TENS on low back region as an analgesic current. Also regular exercise program for back and knees improved the functional capacity.

As a result, patients with alkaptonuria need multidisciplinary evaluation. It should be known that disability related to pain and restriction of joint mobility limits the functional capacity. Patients mostly have additional diseases such as chronic renal failure which may limit our treatment. Therefore physical therapy modalities can be used as an alternative treatment and should also be taken in to consideration in the treatment of musculoskeletal symptoms.

REFERENCES

1. Albers SE, Brozena SJ, Glass LF, Fenske NA. Alkaptonuria and ochronosis: case report and review. *J Am Acad Dermatol*, 1992; 27:609-614
2. Kottinen YT, Hoikka V, Landtman V, Santavirta S, Metsarinne K, Seegmiller JE. Ochronosis: a report of a case and a review of literature. *Clin Exp Rheumatol*, 1987; 7:435-444
3. Garcia SF, Egbert B, Swetter SM. Hereditary ochronosis: hyperpigmented skin overlying cartilaginous structures. *Cutis*, 1999; 63:337-338.
4. Selvi E, Manganelli S, Benucci M, Marcolongo R. Chronic ochronotic arthritis: clinical, arthroscopic and pathologic findings. *J Rheumatol*, 2000; 27:2272-2274.
5. Morava E, Kosztolanyi G, Engelke U, Wevers RA. Reversal of clinical symptoms and radiographic abnormalities with protein restriction and ascorbic acid in alkaptonuria. *Ann Clin Biochem*, 2003; 40:108-111.
6. Thacker M, Garude S, Puri A. Ochronotic arthropathy: arthroscopic findings in the shoulder and the knee. *Arthroscopy*, 2003; 19(8):99-102.
7. Demir S. Alkaptonuric ochronosis: a case with multiple joint replacement arthroplasties. *Clin Rheumatol*, 2003; 22:437-439.
8. Mission N, Van Ruyseveldt CH, Mullier J. Imaging in alkaptonuria. *J Belge Radiol*, 1996; 79:72-73.
9. Mestan MA, Bustin GL, Wagner LA. Chiropractic care and ochronotic arthropathy. *J Manipulative Physiol Ther*, 1999; 22:473-477
10. Emel E, Karagöz F, Aydın H, Seyithanoglu MH. Alkaptonuria with lumbar disc herniation. *Spine*, 2000; 25(16):2141-2144.
11. Wolf JA, Barshop B, Nyhan WL et al. Effects of ascorbic acid in alkaptonuria: alterations in benzoquinone acetic acid and an otogenic effect in infancy. *Pediatr Res*, 1989; 26:140-144.

